

## ORIGINAL ARTICLE

# Evaluation of a retinol containing topical treatment to improve signs of neck aging

Kelly Sullivan MD FCAS<sup>1</sup> | Robert M. Law MD FCAP<sup>2</sup> | Edward Lain MD MBA<sup>3</sup> |  
Lily I. Jiang PhD<sup>4</sup> | Summer F. Acevedo PhD<sup>4</sup> | Hina Choudhary Pharm D<sup>5</sup> |  
Brittany Lee MS<sup>6</sup> | Komal Patel BS<sup>6</sup> | Stephen Lynch PhD<sup>6</sup>

<sup>1</sup>Sullivan Surgery & Spa, Annapolis, Maryland, USA

<sup>2</sup>ProPath, Dallas, Texas, USA

<sup>3</sup>Sanova Dermatology, Austin, Texas, USA

<sup>4</sup>SGS Stephens Inc., Richardson, Texas, USA

<sup>5</sup>SkinCeuticals, New York, New York, USA

<sup>6</sup>L'Oréal Research and Innovation, Clark, New Jersey, USA

## Correspondence

Stephen Lynch, L'Oréal Research and Innovation, Clark, NJ, USA.  
Email: [stephen.lynch@rd.loreal.com](mailto:stephen.lynch@rd.loreal.com)

## Abstract

**Background:** The neck region is an area that can be indicative of signs of skin aging. A novel topical product that combines multiple active ingredients including retinol, tripeptide and glaucine was formulated to specifically target neck aging correction and complement post-procedure as part of an integrated skincare regimen.

**Objectives:** To evaluate the efficacy of a topical neck treatment through clinical subject evaluation, in addition to ultrasound and biopsy assessment.

**Methods:** Evaluation for the efficacy of this novel topical product on improving the aging signs of neck skin was performed in multiple clinical trials. The first trial focused on clinical efficacy and included clinical assessment, subject questionnaires, ultrasound imaging and digital photographs. The second trial focused on biomarker analysis through skin biopsy.

**Results:** Data from the clinical trials showed that aging signs on the neck were significantly improved after 12 or 16 weeks of product usage. Changes were readily observed by clinical evaluators and participants. They were documented with digital photos, ultrasound images, and biomarker expression in the skin which clearly display the improvements.

**Conclusions:** This novel topical product is effective in treating the aging signs on the neck skin and has been shown to provide statistically significant improvement on a myriad of neck aging attributes including fine lines/wrinkles, crepiness, laxity, and texture.

## KEYWORDS

clinical trial, neck, photoaging of the skin, retinol

This is an open access article under the terms of the [Creative Commons Attribution](https://creativecommons.org/licenses/by/4.0/) License, which permits use, distribution and reproduction in any medium, provided the original work is properly cited.

© 2023 The Authors. *Journal of Cosmetic Dermatology* published by Wiley Periodicals LLC.

## 1 | INTRODUCTION

Photo-aged skin is characterized by the presence of fine lines and wrinkles, hyperpigmentation, and the loss of firmness and elasticity, among other alterations following chronic sun exposure. These characteristics arise due to the degradation of collagen, decrease in the amount of water held in the dermis and the epidermis, specifically the stratum corneum, and damage to the additional structural components of the skin such as elastin fibers.<sup>1-3</sup>

An area that is greatly impacted by the aging process is the neck. Neck skin aging is subtle but progressive. Due to the neck's anatomy, it ages differently from the face and has its own specific signs of aging. Aging signs include horizontal rhytids, skin laxity, loss of submental contour, discoloration due to sun exposure, and crepiness due to skin thinning.<sup>4-6</sup> Additionally, the skin on the neck is susceptible to lines and wrinkles from repetitive movements such as looking down at mobile devices.<sup>4-6</sup> Treatment of the neck skin remains a challenge and topical treatment options are limited.<sup>7-10</sup>

A topical cream has been formulated for treatment of neck aging by combining three powerful ingredients. Retinol is the gold standard for improving the appearance of fine lines, wrinkles, and discoloration.<sup>11-13</sup> Tripeptide concentrate, a blend of low molecular weight tripeptide, helps strengthen the skin to build resilience and firm the skin.<sup>14</sup> Glaucine is alkaloid derived from the yellow poppy seed plant and has been shown to support skin's resistance to aging by promoting lipolysis of adipocytes.<sup>15</sup> These active ingredients were combined and formulated specifically for treating the aging signs of the neck skin. Two clinical trials were conducted to fully assess the efficacy of this topical product. Data from clinical evaluations, instrument assessment, photographs, subjects' self-assessment, and biomarker expression all supported the efficacy of the product in improving the appearance of aging neck skin.

## 2 | METHOD

### 2.1 | Subject selection

Female subjects presenting mild to moderate aging signs at the neck area, including fine lines/wrinkles, crepiness, sagging, lack of firmness, lack of elasticity, and uneven skin tone, were selected to participate the clinical trials. The first clinical trial recruited 60 subjects of age 40–60 years, and 50 subjects completed the trial (Table 1). The second clinical trial recruited 15 subjects of age 55–75 years, and 11 subjects completed the trial with neck skin biopsy samples taken at baseline and final visit (Table 2).

Prior to study participation, informed consent conforming to Title 21 Code of Federal Regulations (CFR) 50.25 was obtained from all subjects. Clinical trial involving biopsy procedure was reviewed and approved by IntegReview IRB (Austin) prior to study start.

TABLE 1 Summary of demographics for clinical trial #1.

All subjects		
N	50	
Age (years)		
Mean	53.3	
Standard deviation	5.0	
Minimum	41	
Median	54.0	
Maximum	60	
	N	(%)
Sex		
Female	50	(100.0)
Ethnicity		
Hispanic or Latino	3	(6.0)
Not Hispanic or Latino	47	(94.0)
Race		
Asian	4	(8.0)
Black or African American	5	(10.0)
White or Caucasian	41	(82.0)
Fitzpatrick skin type		
I	1	(2.0)
II	20	(40.0)
III	22	(44.0)
IV	2	(4.0)
V	5	(10.0)
Skin type		
Normal	19	(38.0)
Dry	5	(10.0)
Combination	24	(48.0)
Oily	2	(4.0)
Sensitive skin	8	(16.0)

### 2.2 | Trial design

The two clinical trials were conducted at different testing centers. The first trial was 16 weeks long with the focus on non-invasive clinical assessments. It was conducted from September 2019 to January 2020. The second clinical trial was 12 weeks long with the focus on biomarker changes via skin biopsy analysis. It was conducted in 2020 during the covid-19 pandemic. Subjects applied the product from the jawline to décolletage to cover the entire neck and décolleté area once daily for the first week, then twice daily from the second week on. Subjects used provided moisturizing sunscreen (SPF 50) throughout the trials.

### 2.3 | Clinical assessments

#### 2.3.1 | Clinical evaluations

Aging signs on the neck were evaluated once a month at baseline and Week 4, 8, 12, and 16 visits. Clinical grading parameters included fine

TABLE 2 Summary of demographics for clinical trial #2.

All subjects		
N	11	
Age (years)		
Mean	62.6	
Standard deviation	6.6	
Minimum	55	
Median	60.0	
Maximum	74	
	N	(%)
Sex		
Female	11	(100.0)
Ethnicity		
Not Hispanic or Latino	11	(100.0)
Race		
White or Caucasian	11	(100.0)
Fitzpatrick skin type		
II	3	(27.3)
III	8	(72.7)
Skin type		
Combination	2	(18.2)
Oily	9	(81.8)
Sensitive skin		
No	11	(100.0)

lines/wrinkles (including horizontal lines), visual crepiness, visual and tactile skin smoothness, firmness, elasticity, lifting, and skin tone evenness. Modified Griffiths 10-point scale was used according to the following definition<sup>16</sup>:

0 = none (best possible condition).

1–3 = mild.

4–6 = moderate.

7–9 = severe (worst possible condition).

Tolerability and safety grading was also performed at baseline Weeks 1 and 2 visits, and monthly visits to monitor any potential skin irritation and adverse reactions. Cutaneous tolerability was evaluated by assessing the signs of erythema, edema, dryness/scaling, and peeling, and by subject reporting of the degree of burning, stinging, itching, and tightness on the global neck.

### 2.3.2 | Photography

Digital images of each subject's neck and décolletage were taken at baseline and Weeks 4, 8, 12, 16 visits using Stephens photo station. Canon Mark II 7D digital SLR camera (Canon Inc.) with a Canon EF-S 60 mm f/2.8 macro lens was used with light provided by Profoto D1 (500W) studio strobes affixed to the photo station. Canon EOS utility software was used for image overlay to ensure post-baseline images matched baseline images. Center view and side views (90° left

and 90° right) were taken under visible and cross-polarized lighting modes.

### 2.3.3 | Ultrasound imaging and assessment

Ultrasound imaging was performed using Mindray M7 Ultrasound system (UMI) with a probe set at 7.5 MHz. Image was taken on each subject's submental area approximately midway between the earlobe and chin (just below the jawline) at baseline and Weeks 4, 8, 12, 16 visits. Images taken at baseline and Week 16 were analyzed by an independent CRO for the area and tissue thickness of the superficial adipose tissue, defined as the area from dermis to fascia. Three images per time point were analyzed and the averaged result was used for statistical comparisons.

### 2.3.4 | Subject questionnaire

Subjects completed self-assessment questionnaires regarding product performance at baseline after in-clinic product application and Weeks 4, 8, 12, 16 visits.

## 2.4 | Biopsy collection and histology

Elliptical, full-thickness biopsies were obtained from 11 subjects at baseline (left side of the neck) and Week 12 (right side of the neck) using standard sterile technique after an intradermal local anesthesia. The biopsies samples were fixed in 10% formalin solution and sent for analysis. Hematoxylin and eosin staining was performed, as was immunohistochemistry for pro-collagen, collagen IV, elastin, fibrillin, lumican, and decorin. Staining pattern/intensity was scored and stained tissue section images were taken.

## 2.5 | Statistical analysis

Data collected from the clinical trials were subjected to statistical analysis using SAS software version 9.4 (SAS Statistical Institute). A Shapiro–Wilk test was used to first test for normality of the baseline data (T<sub>0</sub>) and the change from baseline data (T<sub>n</sub>–T<sub>0</sub>) at post-baseline time points at significance level alpha = 0.01. When data passed normality (all normality of the distributions was confirmed for the same parameter), a parametric test was used to test the null hypothesis that the mean change from baseline is zero. When data failed normality (if one or more normality of the distributions for the same parameter was rejected), a nonparametric test was used.

Mean of the change from baseline (defined as post-baseline value minus baseline value) was estimated at applicable post-baseline time points. The null hypothesis is that the mean change from baseline is zero. All statistical tests were done as 2-sided at significance level alpha = 0.05.

### 3 | RESULTS

#### 3.1 | Efficacy assessment

Overall results from the clinical trials indicate that the novel topical neck cream was effective in improving skin conditions on the neck when used over the course of 12 or 16 weeks by women with mild to moderate signs of neck aging. Results of the clinical grading of efficacy parameters showed a statistically significant improvement in fine lines/wrinkles (including horizontal lines), crepiness (visual), visual smoothness, tactile smoothness, firmness (visual), elasticity (tactile), skin tone evenness, and lifting on the neck at Weeks 4 through 16 when compared with baseline. Over 80% of subjects responded to the treatment with improvement and the percentage mean change ranges from ~15% for lines/wrinkles, firmness, elasticity, and lifting to ~30% for crepiness and smoothness. (Figure 1). The changes are visible in the photographs captured during the course of the study. A few representative before and after photos are shown in Figure 2.

#### 3.2 | Tolerability assessment

About 30% subjects experienced some skin irritation and the majority of them had their product use modified and completed the trials. A total of four subjects discontinued from the two studies due to product related adverse events (AEs), and the remaining discontinued subjects were due to non-product related AEs, non-compliance, or lost to follow up. Most of the irritations were mild in nature, but there was a statistically significant increase in erythema, dryness/scaling, and itching within the first 4–8 weeks of use when compared

with baseline, and in peeling throughout the study (except at Week 12) when compared with baseline. Modified use, such as reduced application frequency until tolerance was established, helped alleviate the situation and most people were able to complete the trial satisfactorily.

#### 3.3 | Subject questionnaire

Results of the self-assessment questionnaires showed that the responses from trial participants were favorable at Weeks 4, 8, 12, and 16 visits. As shown in Figure 3, 75%–95% of all participants reported favorable benefits from the products, with median value of 6.0–7.0 at Week 4 and median value of 7.0–8.0 at Weeks 8, 12, and 16, where value of 5.0 is neutral and 9.0 is most favorable. At 15 min post-application, product ease of application and feel on skin all received favorable responses.

#### 3.4 | Ultrasound imaging and analysis

Ultrasound imaging was taken at the submental area from the side of the neck using a 7.5 MHz probe at baseline and Week 16. Based on the ingredient composition of the product, we anticipated that it may have an effect on the lipolysis of adipocytes.<sup>15</sup> Therefore the 7.5 MHz probe was chosen to acquire images deeper into the skin. The ultrasound images were analyzed for the area and thickness of superficial adipose tissue, which is defined as the area from dermis to fascia. As shown in Figure 4, significant reduction (~10%) in adipose tissue area and thickness was observed. This reduction could potentially change skin structure and improve the appearance of neck sagging.

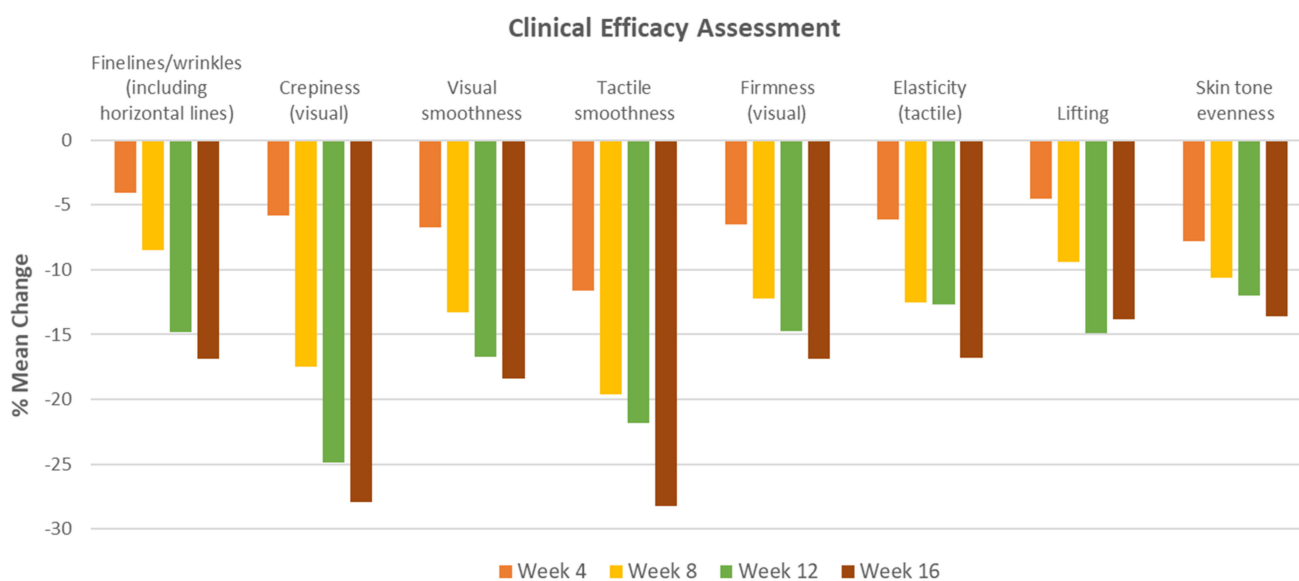
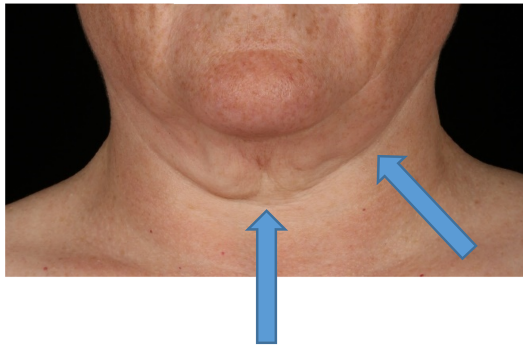


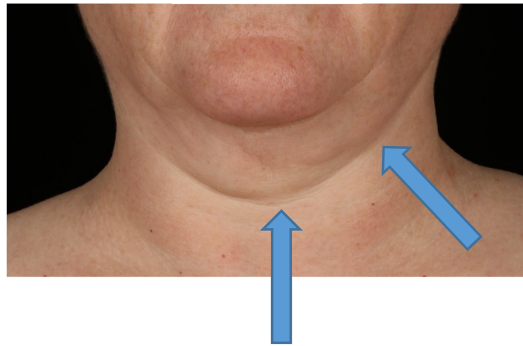FIGURE 1 Bar graph shows the percentage of mean improvement on efficacy parameters of clinical grading assessment at each post baseline time point. All changes are statistically significant ( $p < 0.01$  to  $p < 0.001$ ).

## Subject 050: Fitz I, Caucasian, age 55

Baseline

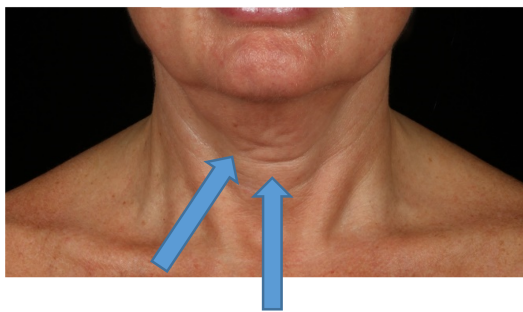


Week 16

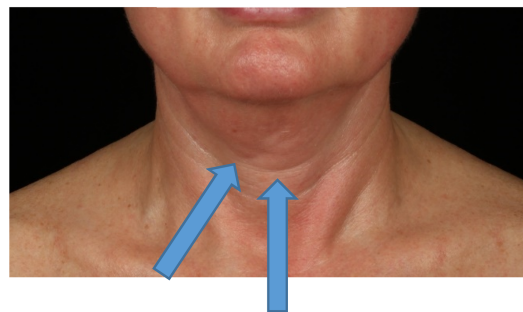


## Subject 043: Fitz III, Caucasian, age 57

Baseline

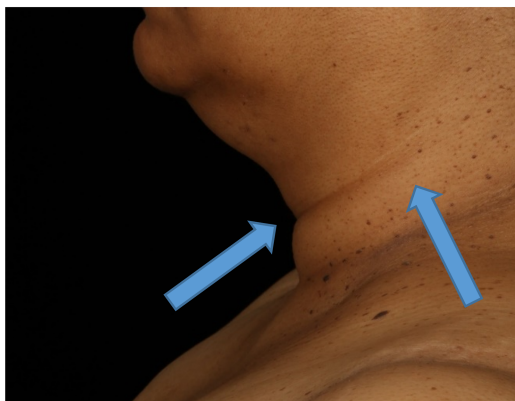


Week 16

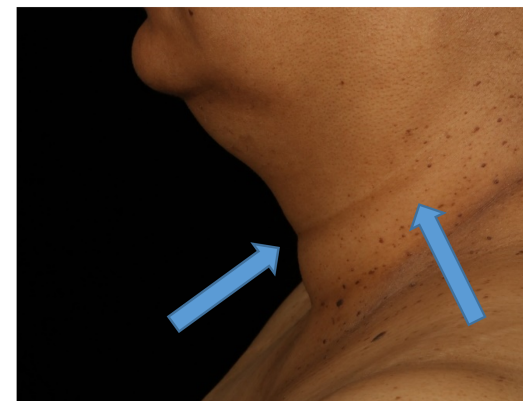

## Subject 028: Fitz V, African American, age 41

Baseline



Week 16

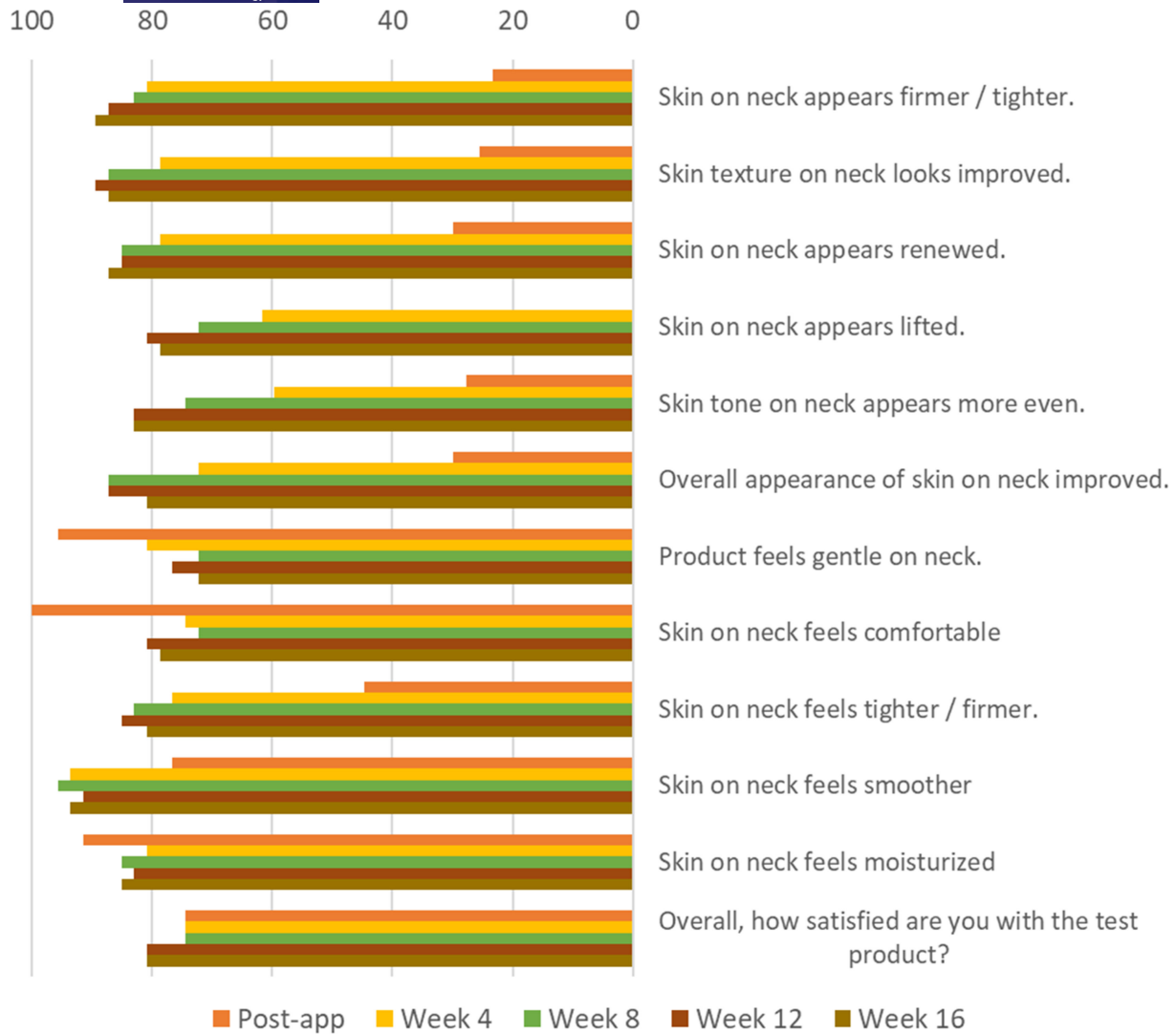


**FIGURE 2** Representative photos showing improvement on the neck skin before and after 16 week of product usage. Average improvement is shown in fine lines/wrinkles and lifting (subject 050), horizontal neck lines (subject 043), and fine lines/wrinkles and skin tone evenness (subject 028). Blue arrows indicate visible improvement on photos.

### 3.5 | Histology

Retinol is known to regulate the expression of a wide range of genes related to skin aging.<sup>17-22</sup> Several targets were selected to be

examined in the skin biopsy samples taken before and after 12 weeks of product usage. The result showed statistically significant increase in the expression of elastin and lumican with 81% and 72% increases in expression scores, respectively at Week 12 (Figures 5 and 6).



**FIGURE 3** Bar graph shows the percentage of subjects reporting positively to the questions during self-assessment at each post baseline time point.

The increase in expression was observed within the interstitium and cytoplasm of dermal fibroblasts. Expression of pro-collagen and fibrillin also showed marginal increase. These changes are consistent with established results that retinoic acid stimulates gene expressions and regulates the organization of collagen fibrillogenesis and elastin fiber matrix.<sup>17-22</sup>

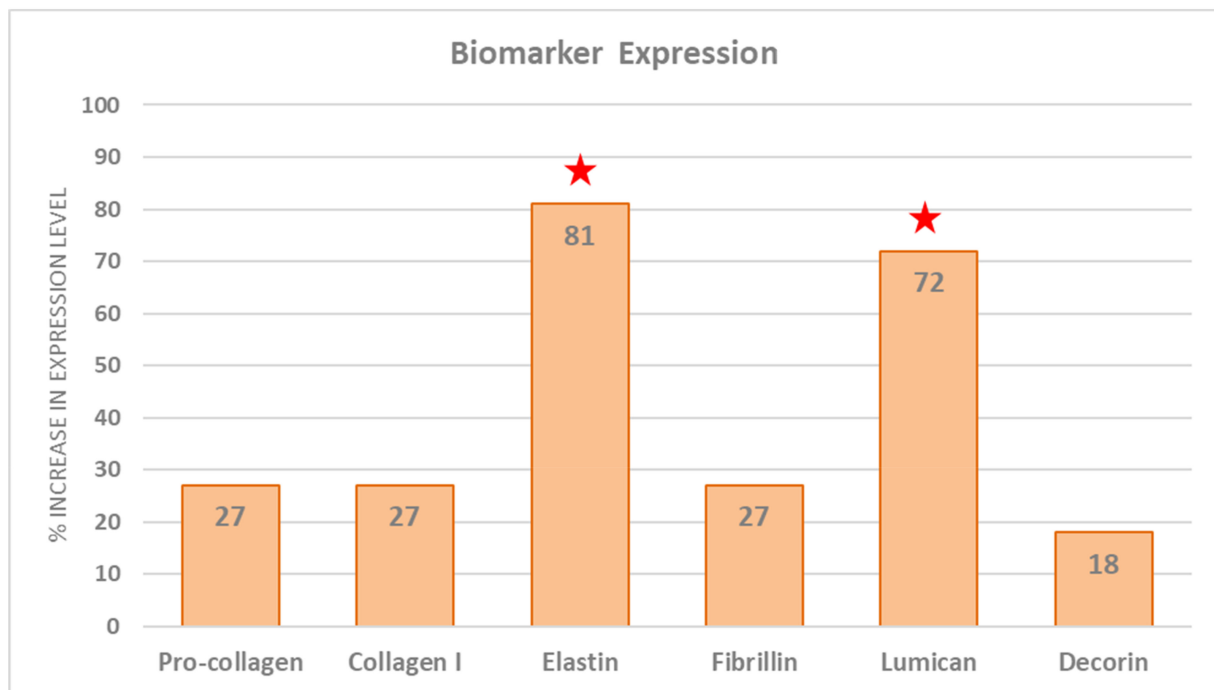
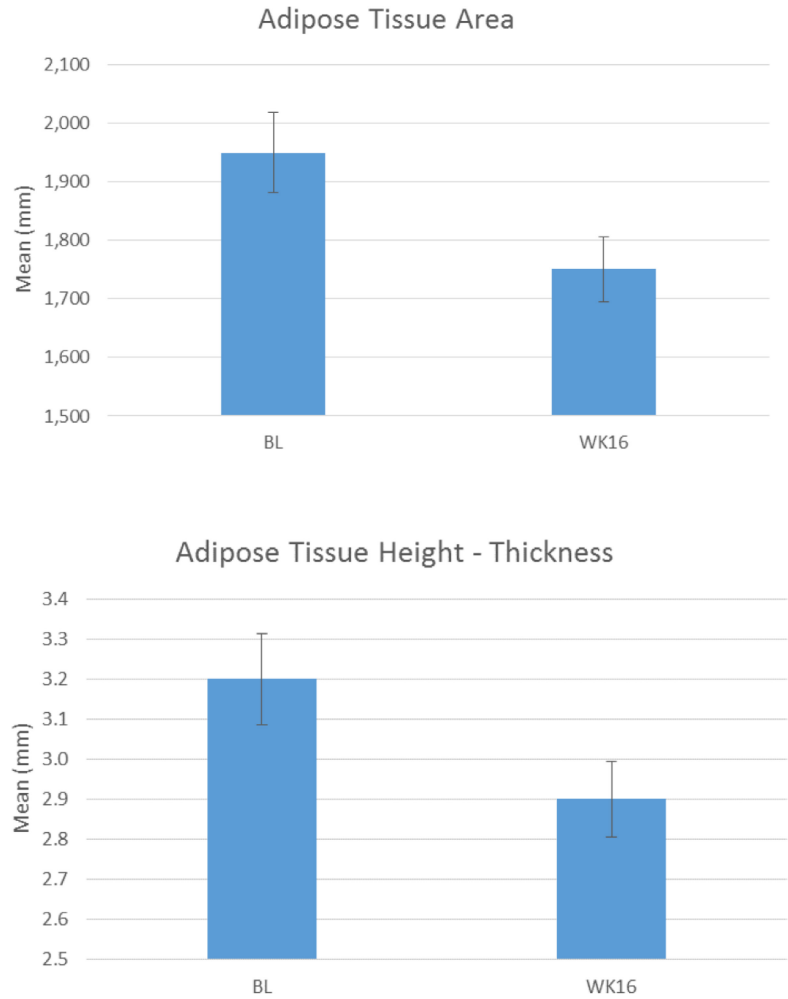
#### 4 | DISCUSSION

Neck skin aging and its treatment has become an interesting and focused area in recent years due to its challenge and the limited treatment options.<sup>7-10</sup> Here we report that a novel topical cream was formulated specifically to treat the aging signs on the neck. This topical cream combines three known active ingredients, retinol, tripeptide complex, and glucaine, which complement each other for optimal benefit to the skin.<sup>11-15</sup> Retinol is a well-established anti-aging ingredient. It has been shown that, when delivered to the skin, it

can modulate the expression of multiple targets that promote skin rejuvenation.<sup>17-22</sup> In addition, glucaine has been shown to promote lipolysis of adipocytes in vitro.<sup>15</sup> Reduction of subcutaneous fat tissue could help tighten and reshape the skin to improve skin firmness and the appearance of sagging.

The efficacy of this topical cream was tested rigorously through two clinical trials. Multiple lines of evidence showed that the novel topical cream is efficacious in improving the aging signs on the neck skin. First, clinical evaluations of the neck aging conditions showed that after 16 weeks of product usage on the neck, there was statistically significant improvement in lines/wrinkles (including horizontal lines), skin smoothness, skin tone evenness, skin crepiness, and importantly skin firmness, elasticity, and neck lifting appearance. Significant improvement was observed as early as Week 4. At Week 16, over 80% participants showed signs of improvement with percentage mean change ranging from 15% to 30%. (Figures 1 and 2). Second, subject self-assessment questionnaire responses indicated that majority of participants observed

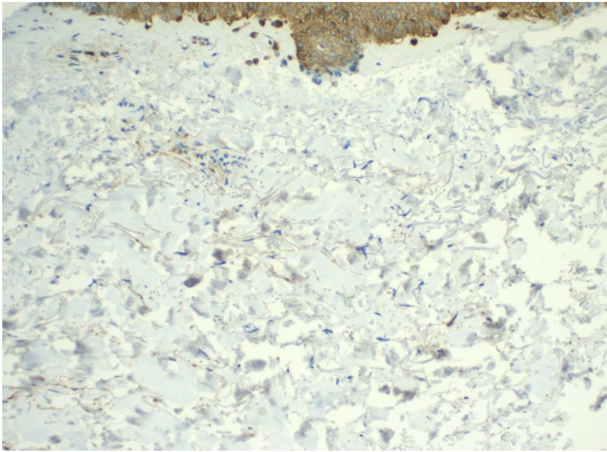
**FIGURE 4** Bar graphs show the reduction of adipose tissue area and thickness at Week 16 comparing to baseline values. The changes are statistically significant ( $p < 0.001$ ).



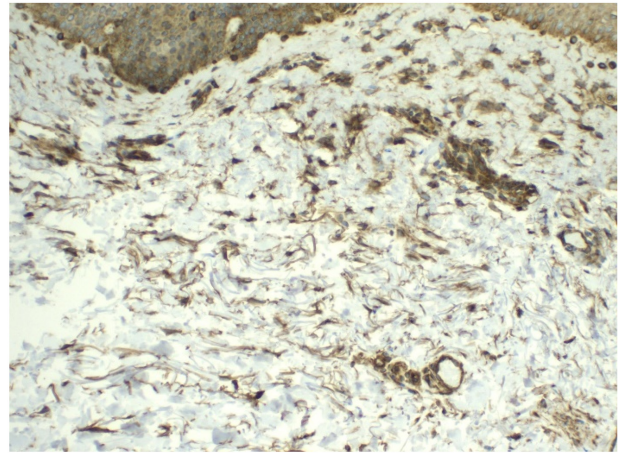
**FIGURE 5** Bar graph shows percentage increase in biomarker expression in biopsy samples at Week 12 compared to baseline. Red asterisks indicate statistically significant change ( $p = 0.005$  for elastin and  $p = 0.016$  for lumican).

## Lumican (subject #007)

## (A) Baseline

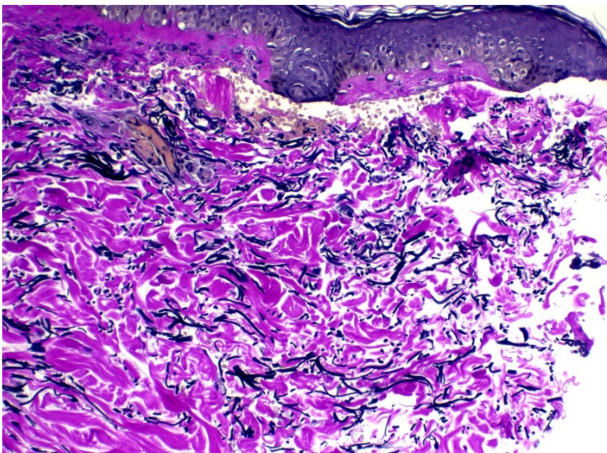


## (B) Week 12

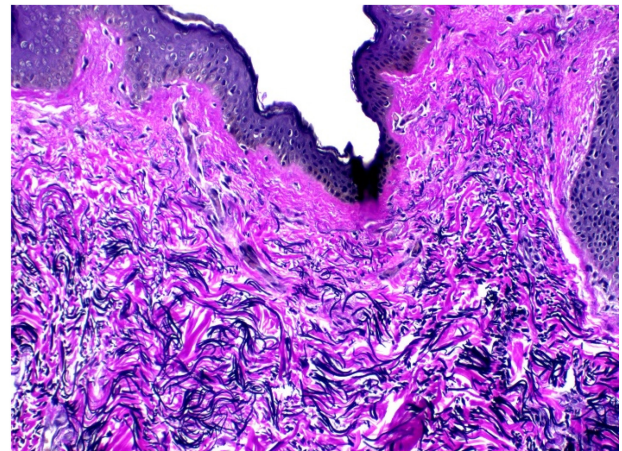


## Elastin (subject #007)

## (C) Baseline



## (D) Week 12



**FIGURE 6** Example of biomarker expression at baseline and at Week 12 from subject 007. (A) & (B): lumican expression; (C) & (D): elastin expression.

benefits from the topical cream and were satisfied with the improvement. (Figure 3). Third, ultrasound imaging revealed a significant reduction of superficial adipose tissue underneath the skin after 16 weeks of product usage. Reduction of subcutaneous fat can lead to skin tightening and reshaping therefore improving the appearance of neck sagging.

Furthermore, biomarker expression was analyzed on skin biopsy samples from 11 subjects taken before and after product usage. Retinoic acid can regulate the expression of multiple genes that are related to skin rejuvenation. Among the known targets of retinoic acid, six were examined during this trial and all six showed varying degree of upregulation with changes in lumican and elastin showing statistical significance of upregulation after 12 weeks of product usage (Figures 5 and 6). Lumican plays an important role

in organizing collagen fibrillogenesis. Well-organized collagen matrix and more elastin expression are hallmarks of young skin.<sup>17-22</sup> Together these results support the observed changes on the skin surface.

One of the drawbacks of retinol containing products is their side effect of skin irritation.<sup>12</sup> This is especially important for the neck skin as it is thinner and more delicate. About 30% of trial participants reported some skin irritation responses. Most were mild in nature and occurred during the first 4 weeks of the trial. A prescribed quantity of product application as opposed to liberal application and less frequent use during the initial weeks of the study may have allowed the skin to better accommodate to this product, especially for subjects who may not have used any retinol products on the neck in the past. Most of the subjects were able to tolerate the irritations and



completed the trials with modified product usage for certain periods of the time; only four subjects from the two studies combined discontinued due to product related AEs. Despite the irritations experienced by some subjects, the neck cream was found to be effective, and from the questionnaire responses, the subjects well appreciated the cosmetic benefits.

To further explore the potential use of this topical product as part of the integrated skincare regimen to complement procedure treatment, an exploratory randomized clinical study was conducted in 38 subjects over the course of 12 weeks. In this study, subjects were assigned to either cell 1 (topical neck cream + CoolMini™) or cell 2 (CoolMini™ alone). Subjects applied the topical cream as per instructions for use, in addition to a supporting moisturizer and SPF 50. The tolerability evaluation was similar to that of the studies reported here, which is expected of initial use of a retinoid containing product. Results of the self-assessment questionnaires showed that the neck cream was well perceived by the subjects regarding ease of use and overall satisfaction (data not shown).

Overall, the efficacy studies demonstrated the novel topical neck cream worked well for combating aging attributes associated with the neck region, thus providing a new option for the treatment of neck aging. Additionally, further clinical testing demonstrated the neck cream can potentially serve as a complement as part of an integrated skincare regimen post-procedure.

#### AUTHOR CONTRIBUTIONS

Kelly Sullivan, Edward Lain, Lily I. Jiang, and Summer F. Acevedo served as investigators on the clinical studies. Robert M. Law performed the skin biopsy sample analysis. Hina Choudhary, Brittany Lee, Komal Patel, and Stephen Lynch designed the studies and reviewed the study results. Lily I. Jiang, Hina Choudhary, and Stephen Lynch wrote the manuscript, all authors reviewed the manuscript.

#### ACKNOWLEDGMENTS

The authors express their gratitude to staff at SGS Stephens Inc. and Sullivan Surgery & Spa for executing the clinical studies.

#### CONFLICT OF INTEREST STATEMENT

This project is funded by SkinCeuticals.

#### DATA AVAILABILITY STATEMENT

The data that support the findings of this study are available from the corresponding author upon reasonable request.

#### ETHICS STATEMENT

The clinical studies were conducted following Good Clinical Practice (ICH E6). Prior to study participation, informed consent conforming to Title 21 Code of Federal Regulations (CFR) 50.25 was obtained from all subjects. Clinical trial involving biopsy procedure was reviewed and approved by IntegReview IRB (Austin, TX) prior to study start.

#### REFERENCES

1. Taylor CR, Stern RS, Leyden JJ, Gilchrist BA. Photoaging/photodamage and photoprotection. *J Am Acad Dermatol*. 1990;22(1):1-15.
2. Chung JH, Seo JY, Choi HR, et al. Modulation of skin collagen metabolism in aged and photoaged human skin in vivo. *J Invest Dermatol*. 2001;117(5):1218-1224.
3. Fligel SE, Varani J, Datta SC, Kang S, Fisher GJ, Voorhees JJ. Collagen degradation in aged/photodamaged skin in vivo and after exposure to matrix metalloproteinase-1 in vitro. *J Invest Dermatol*. 2003;120(5):842-848.
4. Ha RY, Nojima K, Adams WP Jr, Brown SA. Analysis of facial skin thickness: defining the relative thickness index. *Plast Reconstr Surg*. 2005;115(6):1769-1773.
5. Kim E, Cho G, Won NG, Cho J. Age-related changes in skin biomechanical properties: the neck skin compared with the cheek and forearm skin in Korean females. *Skin Res Technol*. 2013;19:236-241.
6. Shadfar S, Perkins SW. Anatomy and physiology of the aging neck. *Facial Plast Surg Clin North Am*. 2014;22:161-170.
7. Rohrich RJ, Rios JL, Smith PD, Gutowski K. Neck rejuvenation revisited. *Plast Reconstr Surg*. 2006;118:1251-1263.
8. Vanaman M, Fabi SG, Cox SE. Neck rejuvenation using a combination approach: our experience and a review of the literature. *Dermatol Surg*. 2016;42(Suppl 2):S94-S100.
9. Perez MI. An anatomic approach to the rejuvenation of the neck. *Dermatol Clin*. 2001;19(2):387-396.
10. Fulton JE, Rahimi AD, Helton P, Dahlberg K. Neck rejuvenation by combining Jessner/TCA peel, dermasanding, and CO2 laser resurfacing. *Dermatol Surg*. 1999;25(10):745-750. doi:10.1046/j.1524-4725.1999.98298.x
11. Bruce S, Barkovic S. Open-label study evaluating the anti-aging effects of a 3-product, 2-step retinol-rejuvenation system following 3 months of treatment in subjects with photodamage. *J Drugs Dermatol*. 2017;16(1):23-28.
12. Lowe PM, Woods J, Lewis A, Davies A, Cooper AJ. Topical tretinoin improves the appearance of photo damaged skin. *Australas J Dermatol*. 1994;35(1):1-9. doi:10.1111/j.1440-0960.1994.tb01790.x
13. Leyden JJ, Parr L. Treating photodamage of the décolletage area with a novel copper zinc malonate complex plus hydroquinone and tretinoin. *J Drugs Dermatol*. 2010;9(3):220-226.
14. Pickart L. The human tri-peptide GHK and tissue remodeling. *J Biomater Sci Polym Ed*. 2008;19(8):969-988. doi:10.1163/156856208784909435
15. Al-Bader T, Byrne A, Gillbro J, et al. Effect of cosmetic ingredients as anticellulite agents: synergistic action of actives with in vitro and in vivo efficacy. *J Cosmet Dermatol*. 2012;11(1):17-26. doi:10.1111/j.1473-2165.2011.00594.x
16. Griffiths CE, Wang TS, Hamilton TA, Voorhees JJ, Ellis CN. A photometric scale for the assessment of cutaneous photodamage. *Arch Dermatol*. 1992;128(3):347-351.
17. Shao Y, He T, Fisher GJ, Voorhees JJ, Quan T. Molecular basis of retinol anti-ageing properties in naturally aged human skin in vivo. *Int J Cosmet Sci*. 2017;39(1):56-65. doi:10.1111/ics.12348
18. Gasimli L, Stansfield HE, Nairn AV, et al. Structural remodeling of proteoglycans upon retinoic acid-induced differentiation of NCCIT cells. *Glycoconj J*. 2013;30(5):497-510. doi:10.1007/s10719-012-9450-x
19. Karamanou K, Perrot G, Maquart FX, Brézillon S. Lumican as a multivalent effector in wound healing. *Adv Drug Deliv Rev*. 2018;129:344-351. doi:10.1016/j.addr.2018.02.011
20. Chakravarti S, Magnuson T, Lass JH, Jepsen KJ, LaMantia C, Carroll H. Lumican regulates collagen fibril assembly: skin fragility and corneal opacity in the absence of lumican. *J Cell Biol*. 1998;141(5):1277-1286. doi:10.1083/jcb.141.5.1277
21. Kähäri VM, Häkkinen L, Westermarck J, Larjava H. Differential regulation of decorin and biglycan gene expression by

- dexamethasone and retinoic acid in cultured human skin fibroblasts. *J Invest Dermatol.* 1995;104(4):503-508. doi:[10.1111/1523-1747.ep12605969](https://doi.org/10.1111/1523-1747.ep12605969)
22. Rossetti D, Kielmanowicz MG, Vigodman S, et al. A novel anti-ageing mechanism for retinol: induction of dermal elastin synthesis and elastin fibre formation. *Int J Cosmet Sci.* 2011;33(1):62-69. doi:[10.1111/j.1468-2494.2010.00588.x](https://doi.org/10.1111/j.1468-2494.2010.00588.x)

**How to cite this article:** Sullivan K, Law RM, Lain E, et al. Evaluation of a retinol containing topical treatment to improve signs of neck aging. *J Cosmet Dermatol.* 2023;00:1-10. doi:[10.1111/jocd.15904](https://doi.org/10.1111/jocd.15904)